Neurological Surgery and Anatomy 2026, 3(2): 40-45, e-ISSN: 2966-0696
DOI: 10.37085/nsa.2026.8

Original

Skull in 3D: a pioneering multidisciplinary approach

Carolina Martins[1,4], Florisvaldo José Morais de Vasconcelos Junior[1], Guilherme Cristiano Garcia[2], Leíla Maria Ferraz Santiago[3], Gabriel Melo Duarte Costa[3], Isaías Henrique Martins Vasconcelos Norte Bezerra[2], Renata Cristinny de Farias Campina[1], Anderson Arnaldo da Silva[1], Ana Cristina Falcão Esteves[1], Valdenice Rumão de Melo[4], Juliana Ramos de Andrade[1,4], Antonio Cavalcanti de Albuquerque Martins[3,4], Marcelo Moraes Valença[1,4]

[1]Federal University of Pernambuco, Recife, Pernambuco, Brazil
[2]University of Pernambuco, Recife, Pernambuco, Brazil
[3]Pernambuco School of Health, Recife, Pernambuco, Brazil
[4]Homo Docens Teaching Platform, Recife, Pernambuco, Brazil

Introduction
Traditional teaching of skull osteology faces limitations in spatial understanding of structures—essential for its practical application. Real 3D visualization, involving construction/deconstruction of the skull, combined with hands-on exploration of cranial compartments, are unprecedented in bridging learning with clinical/surgical, and forensic practice.
Objective
To report the experience of multidisciplinary theoretical-practical courses in skull osteology using 3D visualization, highlighting methodology and post-course evaluations.
Methods
The 2025-26 workshop editions included digital 3D projections and thematic practical stations to present the skull as compartmentalized and integrated construct. Pre- and post-tests, accessible via QR-code, emphasized practical application of knowledge. Participants included undergraduate and graduate students (Residents, Master's and Doctoral candidates), technicians, and professionals from biological sciences, dentistry, physiotherapy, nursing, medicine, and anthropology. Paperless electronic evaluation forms were also completed.
Results
Mean pre-test score was 4.2/10 and post-test 7.5/10, with 87.5% of participants showing improved performance. Overall evaluation recorded 78% satisfaction. Instructor performance stood out, with 78% reporting "exceeded expectations." The most useful aspects identified were clinical and surgical application of content, practice with specimens and instruments, and clarity of 3D visualization. Suggestions included longer practice sessions and expansion to other anatomical regions.
Conclusions
Multidisciplinary Workshop on Skull Osteology in 3D proved to be effective, innovative, and pioneering strategy. Unlike digital initiatives focused on research or modeling, this in-person experience integrates theory and practice, reinforcing the potential of 3D technology as a complementary tool to traditional teaching, fostering interdisciplinary integration, stimulating clinical reasoning, and enhancing anatomical proficiency among students and professionals.

Keywords: Anatomy, Osteology, Skull, Health education, Three-dimensional imaging, Applied neuroanatomy

Edited by:
Hung Tzu Wen

Carolina Martins
maria.cmlima@ufpe.br

Received: July 21, 2026
Revised: September 17, 2026
Accepted: October 26, 2026

© Copyright 2026

Introduction

Traditional teaching of skull osteology struggles with a fundamental weakness: the lack of spatial understanding of structures, which is essential for practical application. Detached from real-world contexts, it often becomes sterile, diminishing the relevance of this knowledge and hindering retention. Without meaningful integration (1), it risks being forgotten precisely when a health professional needs it most.

On the other hand, a curriculum that gradually constructs and deconstructs the skull—based on its individual three-dimensional bony elements—while incorporating developmental and anthropological perspectives, and exploring living anatomy, clinical imaging, and applied skull anatomy, can transform how professionals perceive and learn about this structure. Such a tool has the potential to foster a novel, deeper, and more meaningful understanding of the field.

This study presents and analyzes two annual editions of such a didactic endeavor, highlighting its impact on a multidisciplinary group of participants.

Method

The Multidisciplinary Workshop on Skull Osteology in 3D combined diverse pedagogical resources into a core curriculum that interspersed projection of real three-dimensional anatomical images—used for deconstruction and reconstruction of the human skull—with stations for practical application of this knowledge.

Organized by professors from Anatomy, Neurology/Neurosurgery, and Forensic Anthropology, the course consisted of eight hours of integrated 3D lectures and hands-on practice. Its aim was to enable participants to apply this knowledge in clinical, imaging, surgical, and anthropological contexts, as well as to support research in each of these areas. A dry run was conducted with instructors and monitors to test the course plan, ensuring proper sequence and timing of activities.

The event was led by specialists. A pre-test preceded the 3D presentations, which were delivered using digital projection (Optoma, Xindian District, Taiwan) on a 2×2 m screen. Participants wore active, compatible, shutter glasses (Kesoto, Shenzhen, China). The 3D sessions were interspersed with living anatomy exercises involving palpation of landmarks both at rest and during dynamic muscle activity. Practical stations, attended in rotation, expanded on topics introduced during the 3D lessons and included: a) craniometry b) skull evolution, c) forensic anthropology, d) imaging aspects, and e) surgical approaches.

Each station integrated multiple teaching modalities, such as anthropological models of skull development, digital exercises on craniometric points, forensic analysis using human specimens, and surgical exploration of the nasal corridor with endoscopes. A post-test and anonymous survey followed. All questionnaires (pre-test, post-test, and course evaluation) were online, illustrated, and accessible via QR code in a paperless format.

Statistical analyses were conducted using paired-samples t-tests to compare pre- and post-test scores among participants who completed both assessments. Normality assumptions were checked, and effect sizes were calculated using Cohen's d to estimate the magnitude of improvement. Significance was set at $p < 0.05$. In addition, a Wilcoxon signed-rank test was performed as a non-parametric alternative, confirming the robustness of the findings.

Administrative logistics and participant support were managed in partnership with Homo Docens, the teaching platform supporting this initiative. The syllabus was disseminated online, and registrations were completed digitally. Certificates of participation were issued, and participants received individual feedback on their performance.

In both course editions (2025 and 2026), theoretical 3D sessions were held in a room equipped with blackout curtains, a digital 3D projector, compatible glasses, lapel microphone, sound system, and laser pointer. Practical sessions took place in an adjacent room, with stations identified by colored tablecloths (yellow, blue, red, green) to facilitate group rotation. Each year, one of the partner institutions hosted the event.

A total of 53 participants attended, including undergraduate and graduate students (Residents, Master's and Doctoral candidates), technicians, and professionals from biological sciences, dentistry, physiotherapy, nursing, medicine, and anthropology.

Results

The pre- and post-tests evaluated applications of skull anatomy, using illustrated multiple-choice quizzes. Thirty-three participants (62%) completed the pre-test, with a mean score of 4.2/10. Thirty-four participants (64%) completed the post-test, where the mean score increased to 7.5/10. Among those who completed both tests, 87.5% demonstrated improved performance. Of these, 40.6% improved by 1–3 points, 31.2% by 4–6 points, and 15.6% by 7 or more points. A paired-samples t-test confirmed that post-test scores were significantly higher than pre-test scores (mean difference = 3.3 points, $t(31) \approx 8.2$, $p < 0.001$), with a large effect size (Cohen's $d \approx 1.45$). A non-parametric Wilcoxon signed-rank test yielded consistent results, showing a significant median improvement ($Z \approx -4.9$, $p < 0.001$).

Twenty-three participants accessed the virtual form via QR code and recorded their impressions of the event (Figure 1). Overall evaluation of the workshop showed 78% satisfaction, rated as "excellent" or "exceeded expectations." Instructor performance was particularly notable, with 78% reporting "exceeded expectations," and when combined with those rating "excellent," the total reached 83%, surpassing the overall impression.

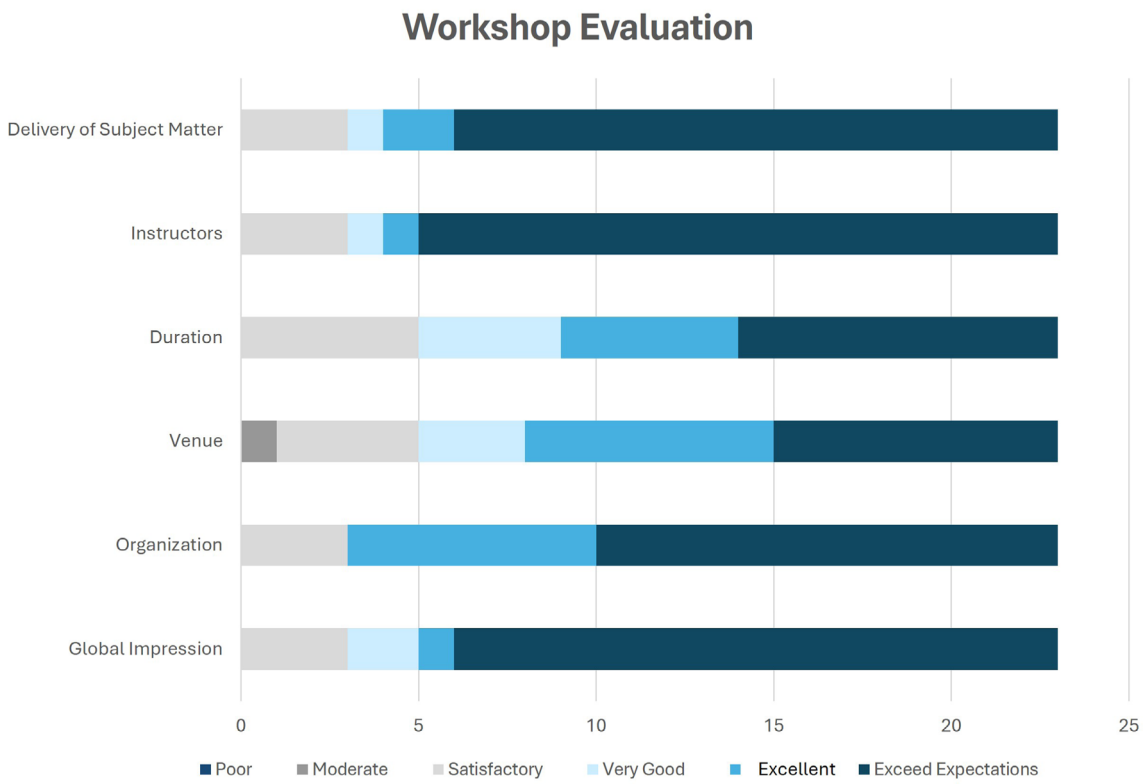

Figure 1. Workshop evaluation summary.

A 5-tier Likert scale was used to rate the quality and objectives of the workshop (Figure 2). The overwhelming majority of participants fully agreed that the workshop's content was organized and well-planned (91%) and it helped reach the objectives set at its starting point. However, only 61% considered the content appropriate for the time. When checking the optional open field included for these questions, and filled by participants (29/53), with suggestions for improvements (19/29), there were suggestions to increase duration or separate the workshop into modules (12/19, 63.2%).

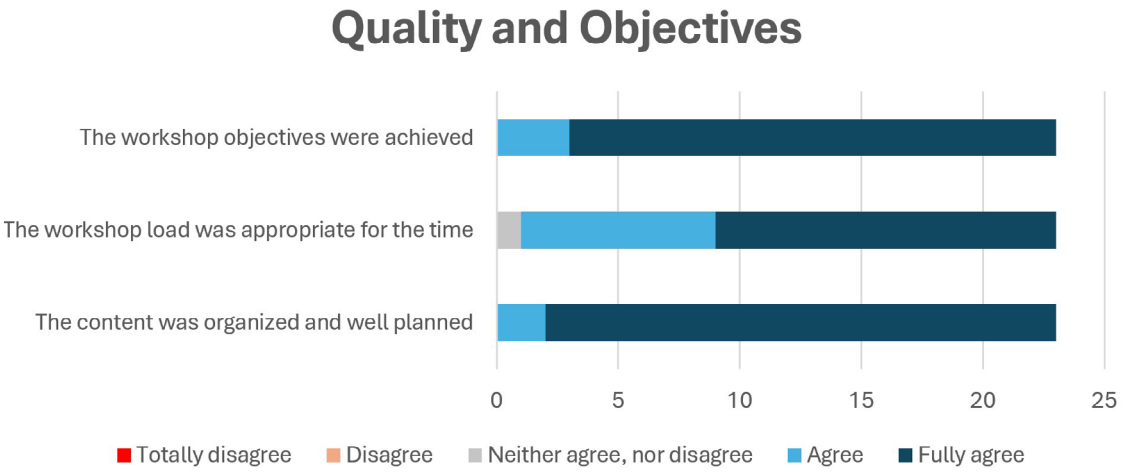

Figure 2. Workshop's quality and objectives evaluation.

Thirty-four participants (64%) took the time to fill in the field, "What did you learn in this course?", the categorization of participants' responses shows that learning extended beyond the nominal area of the event (12%), encompassing other domains as well. It also demonstrated depth (44.1%), integration (26.4%), and application of knowledge (17.6%) (Figure 3), reinforcing the extension-oriented nature of this activity.

When asked to indicate the usefulness of the strategies to the effect of answering 'How did you learn?', participants' responses highlighted, in order, the clinical, surgical, and imaging applications of the knowledge (35.2%), 3D visualization (26.4%), practice with cadaveric specimens and instruments (20.5%), and the teaching methods used in this training (17.6%) (Figure 4).

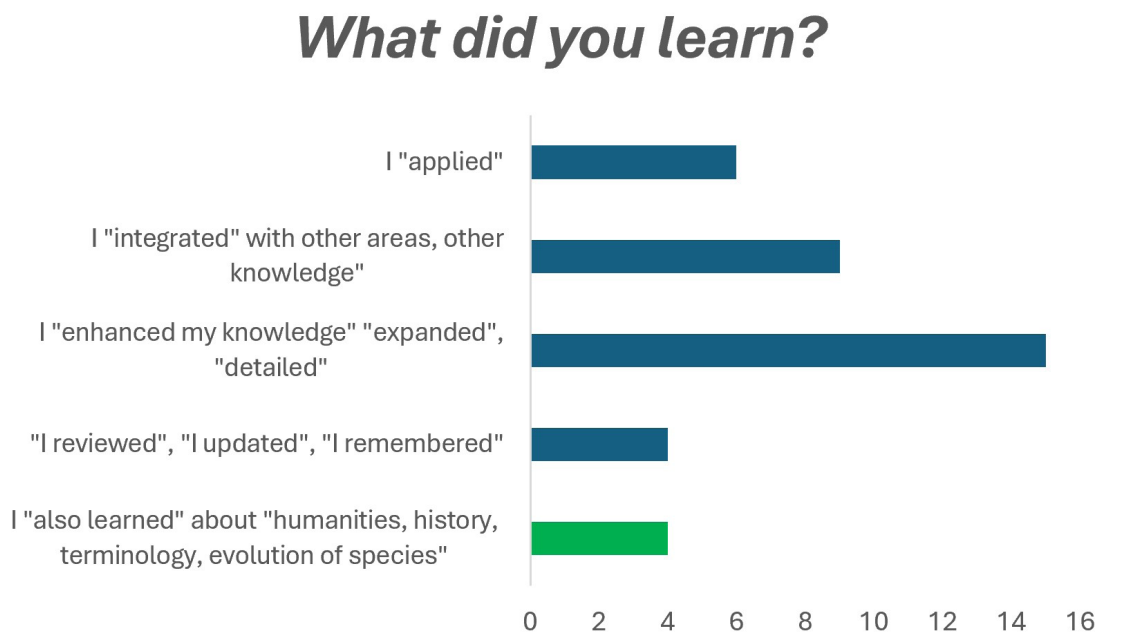

Figure 3. Participants' answers to the question "What did you learn?" were categorized by the verbs employed to describe their experience.

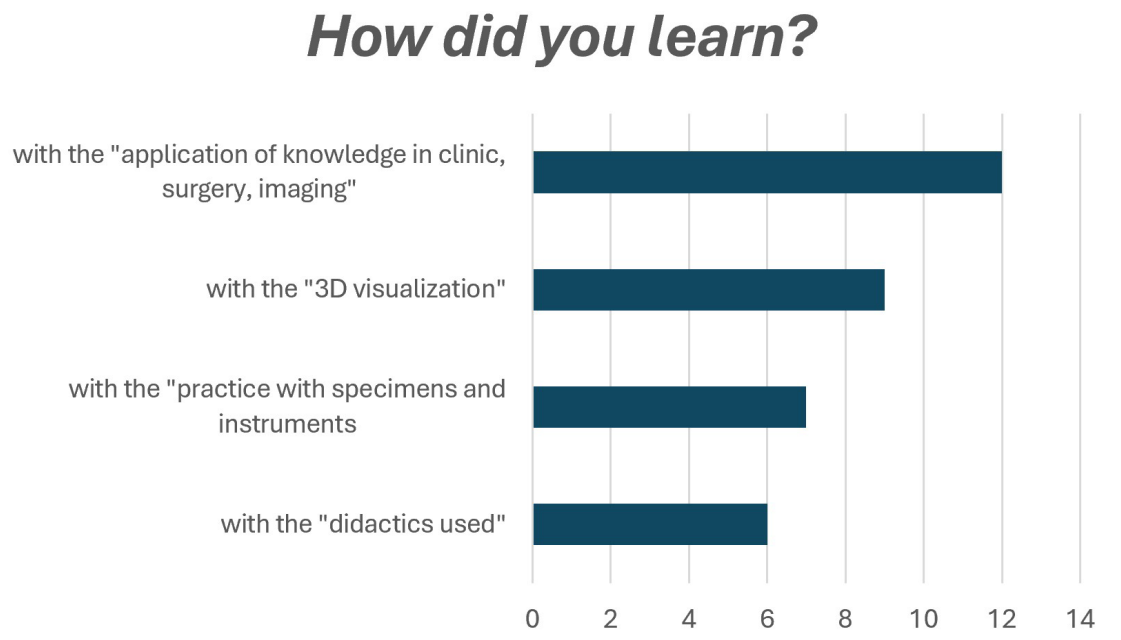

Figure 4. Participants' answers to the question "How did you learn?".

These workshops have generated impact beyond the classroom. Since the inception of the partnership that led to their creation, two directly related national submissions and one international meeting submission have been produced. In addition, a joint multidisciplinary research project has received IRB and Ethics Committee approval (CAAE 93808125100005208) and is currently underway. Furthermore, a request has been submitted for an institutional grant to establish a special working group within the Department of Anatomy, aimed at advancing 3D and Mastery Learning initiatives in applied microneuroanatomy.

Discussion

Although skull osteology is a mandatory part of curricula in Health Sciences, Social Sciences, and studies of human body representations, the level of detail required for modern applications of this knowledge—and its use in research—requires not only three-dimensional understanding but also a solid foundation of the relationships among the bony elements that make up the head. This course provided such immersion in a real three-dimensional format, associated with practical application, under multiprofessional guidance. This format is in itself original and authorial, justifying this report.

Be that as it may, this is the first theoretical-practical event using 3D technology at the Anatomy Department at the Federal University of Pernambuco and the result of a partnership with Homo Docens, an educational platform specialized in events in this modality. The result of this partnership is a new pedagogical format to teach anatomy of the human skull, that incorporates multiple didactical strategies and experts in several fields into a concise, planned approach. This partnership has resulted in other scientific communications, research opportunities and extension activities beyond its initial focus.

The Multidisciplinary Workshop on Skull Osteology in 3D demonstrated that combining diverse pedagogical resources—three-dimensional visualization, living anatomy, cadaveric specimens, and multimodal stations—can significantly enhance learning outcomes. This integrated approach reflects current recommendations that no single teaching tool suffices, but that multimodal strategies provide complementary strengths and improve effectiveness in anatomy education (2). The significant improvement in test scores, alongside high satisfaction rates, confirms the value of this multimodal teaching in fostering both knowledge acquisition and application.

Participants particularly emphasized the clinical, surgical, and imaging relevance of the workshop. This aligns with evidence that cadaveric specimens remain central to education, with surgeons themselves advocating for their reinforcement and for the integration of radiological modalities, especially CT, into anatomy curricula (3). The inclusion of endoscopic practice and imaging stations in the present workshop therefore responds directly to these calls, bridging foundational anatomy with clinical/surgical training and clinical application.

The innovative use of 3D projection based on real stereoscopic pairs (and not single digital imaging reflected in depth)—produced from arrangements of human bony specimens in isolation (and pictured from different points of view), or as combinations into constructive and deconstructive sets—has the power to convey the skull as an integrated structure. This is the underlying message across the workshop, to which additional information is gradually added. This format has been spontaneously recognized by 17.6% of participants as a positive, innovative factor for learning in itself, lining up with other innovative uses of real 3D images in anatomy and anthropology (2–5). Our workshop thus contributes to this broader trajectory of innovation, reinforcing the potential of 3D technologies and mastery learning initiatives in applied microneuroanatomy.

Nonetheless, several limitations must be acknowledged. Participation in pre- and post-tests was incomplete, with only 62–64% of attendees contributing. Although full participation is rarely achieved in voluntary educational evaluations, where typical response rates range from 50% to 70% (6), this level of engagement is consistent with reported norms. Nevertheless, incomplete participation may limit statistical power and introduce potential bias, which should be considered when interpreting our findings.

Time constraints were also evident: while most participants agreed the content was well planned, a substantial proportion suggested longer sessions or modularization. Evaluation relied on short-term test scores and self-reported satisfaction, without long-term follow-up to assess retention or transfer into clinical practice. Finally, although participants came from diverse disciplines, outcomes were not stratified by professional background, limiting insights into discipline-specific needs. These absences mirror broader challenges in anatomy education, including curricular compression, resource limitations, and heterogeneous learner profiles (2), this workshop is in itself a “microcosm” of anatomical teaching as a whole, an understanding that makes our future directions very exciting and should potentially consider to include a) modular or extended formats to address specific groups; b) include other levels of hands on activities as vertical integration into surgical training (to ensure continuity from preclinical to clinical years), invest into c) longitudinal studies to evaluate retention and clinical transfer, and explore how d) integration with digital atlases and 3D printing could expand scalability.

Conclusion

The Multidisciplinary Workshop on Skull Osteology in 3D demonstrated that multimodal, clinically oriented anatomy teaching can significantly improve performance and satisfaction. By combining 3D visualization, cadaveric practice and clinical/surgical imaging, the workshop aligns with best practices in anatomy education and responds to calls from educators for integrated, applied training.

While limitations in participation, time, and evaluation scope remain, the initiative has already generated academic outputs and institutional momentum, positioning it as a promising model for advancing applied microneuroanatomy education.

References

1. McGaghie WC, Barsuk JH, Wayne DB, editors. Comprehensive healthcare simulation: mastery learning in health professions education. Cham: Springer International Publishing; 2020. Doi:10.1007/978-3-030-34811-3.

2. Estai M, Bunt S. Best teaching practices in anatomy education: A critical review. Annals of Anatomy - Anatomischer Anzeiger 2016;208:151–7. Doi:10.1016/j.aanat.2016.02.010.
3. Sheikh AH, Barry DS, Gutierrez H, Cryan JF, O'Keeffe GW. Cadaveric anatomy in the future of medical education: What is the surgeons view? Anat Sci Educ 2016;9:203–8. Doi:10.1002/ase.1560.
4. Lima LFM, Araujo MMF de. Fotogrametria. Um atlas virtual 3D de cranios humanos como principal ferramenta de banco de dados para pesquisa, ensino e identificação de pessoas desaparecidas. Thesis. Federal University of Alfenas, 2026.
5. Sanz-Peña B, Suffo M, Galán-Romero L, Jiménez-Alba A, García-Alcántara V, Iglesias-Lozano I, et al. Development and preliminary validation of a multidisciplinary 3D-printed skull base model for endoscopic endonasal surgical training. 3D Print Med 2026;12. Doi:10.1186/s41205-026-00318-w.
6. StatsGeo. Youth education and training participation rates (ages 15–24) by country. Education. https://statsgeo.com/youth-education-and-training-participation-rates-ages-1524-by-country.

Carolina Martins
https://orcid.org/0000-0002-0197-3520
Florisvaldo José Morais de Vasconcelos Junior
https://orcid.org/0009-0003-0605-1044
Guilherme Cristiano Garcia
https://orcid.org/0000-0002-7647-3408
Leíla Maria Ferraz Santiago
https://orcid.org/0009-0009-6132-7297
Gabriel Melo Duarte Costa
https://orcid.org/0009-0005-8398-458X
Isaías Henrique Martins Vasconcelos Norte Bezerra
https://orcid.org/0009-0002-0102-0022
Renata Cristinny de Farias Campina
https://orcid.org/0000-0001-8256-7040
Anderson Arnaldo da Silva
Ana Cristina Falcão Esteves
https://orcid.org/0009-0006-9313-0286
Valdenice Rumão de Melo
https://orcid.org/0009-0008-9114-1429
Juliana Ramos de Andrade
https://orcid.org/0000-0002-5445-8872
Antonio Cavalcanti de Albuquerque Martins
https://orcid.org/0000-0002-1249-8622
Marcelo Moraes Valença
https://orcid.org/0000-0003-0678-3782

Authors' contributions: FJMVJ, LMFS, GCG, GMDC, IHMVNB, CM, ACAM Data collection and organization, Draft version of the manuscript and literature review; FJMVJ, LMFS, GCG, GMDC, IHMVNB, CM, ACAM, VRM, JRA, MMV, ACFE, AAS, RCFC: Agreement to be accountable for all aspects of the work; VRM, JRA, MMV, ACFE, AAS, RCFC, CM, ACAM: Reviewing the work critically for important intellectual content, Final approval of the version to be published; CM, ACAM: Substantial contributions to the conception of the work, Image selection and treatment; FJMVJ, CM: Contributed equally as first authors of this work.
Conflict of interest: None.
Funding: This research did not receive funding