

Image

The Advent of Modern Brain Surgery: 100 years since William Macewen

Antonio Cavalcanti de Albuquerque Martins¹, Carolina Martins^{1,2},
Marcelo Moraes Valença²

¹Medical School of Pernambuco - FPS, Recife, Brazil

²Federal University of Pernambuco - UFPE, Recife, Brazil

The year 2024 marks one hundred years since the death of the “Father of Modern Brain Surgery”: Sir William Macewen. Unbeknownst to many, the epithet derives from his uncanny ability to conjoin clinical data and anatomical knowledge, to be able to perform accurate localization of intracranial disease and its treatment, as earlier as 1876. Working before the advent of the X-Rays and modern neuroimaging, he published the Atlas of Head Sections, an unsurpassed guide for sectional anatomy of the head. Among his numerous contributions, the authors emphasize images of this publication and its continuing impact to brain and skull base micro and endoscopic surgery.

Keywords

Anatomy, Cross Section, Brain, Head, History of Medicine, William Macewen

Edited by:

Juliana Ramos de Andrade



Antonio Cavalcanti de A Martins
antoniocavalcantideamartins@
gmail.com

Submitted: July 4, 2024
Accepted: August 18, 2024
Published online: August 31, 2024

Introduction

A disciple of Lister, a firm believer in training, and on the power of engaging the complementary powers of a multidisciplinary team, William Macewen (1848-1924) (1,2) excelled in conjoining the clinical and anatomical data to perform accurate localization of intracranial disease.

His accomplishments are many and benefit a vast number of fields (Table 1). The year 2024 marks one hundred years since the death of Sir William Macewen (1848-1924), considered the “Father of Modern Brain Surgery”. The authors highlight the life of this Scottish surgeon as an example of nous or phronesis - the Aristotelian virtue of applying knowledge to everyday problems.

Furthermore, Macewen’s side-publication: *The Atlas of Head Sections* (9) combines several characteristics that define the man: a) his early enthusiasm with photography as a means of documenting and registering patient’s cases and teaching surgery and medicine (8) – Macewen pioneered the use of photography before, during and after surgery, as well as during follow-ups,

and pictured body parts and pathological specimens (1,3), b) his anatomical knowledge, which is a proto-example of “see-through view” - later championed by Rhoton (6) and his group in guiding the knowledge required for microneurosurgery and c) Macewen’s achieved expertise in recognizing and treating pyogenic disease and abscesses of the head – as *The Atlas* was at first a side-publication to his book *Pyogenic Infections of the Brain and Spinal Cord* (1893). Very soon *The Atlas of Head Sections* stood at its own. It was judged by *Lancet* as one of the two most important medical publications of that year and became the standard atlas, for the next fifty years (3). Since the daily introduction of the endoscope in skull base neurosurgery, once more *The Atlas* has proved its relevance, by giving - as then in the words of Macewen himself:

“...the relations of the various parts of the brain to the outside of the skull exposed in [...] different sections [...]” Consequently, the surgeon who is about to perform an operation on the brain has in these cephalic sections a means of refreshing the memory regarding the position of the various structures which he/[she] is about to encounter” (9).

Table 1: Macewen’s accomplishments and the modern field that benefitted from them.

Year	Development Made	Modern Relevance to the Field of
From 1874 on	Transplanted animal bone to close skull fractures, developed an instrument – the double bevelled osteotome – and a method of implanting small human cadaveric grafts to replace missing parts of limb-bones (the first bone graft). These two last developments probably rested on his woodworking familiarity ³ .	Orthopaedics, Spine Neurosurgery
1876	First autopsy confirmation of Macewen’s anatomical localization of a neurosurgical disease based on with clinical signs (MacKinley case) ^{1,4} . The autopsy confirmation instead of surgical confirmation occurred because the family of the patient refused surgery. Macewen was only 28 years-old and had finished his basic medical training 8 years ago ³ .	Neurosurgery, Neurology Pathology
1879	First successful intracranial surgery with clinical localization (John Daley’s case) ⁴ .	Neurosurgery, Neurology
	Macewen’s operation for inguinal hernia that closes the internal ring with a pad made from the hernia sac, a procedure based on a profound understanding of the abdominal muscles and intestinal mechanics ³ .	General Surgery
	Pioneered orotracheal intubation ⁴ – later adopted for endotracheal anaesthesia	Anaesthesiology, Surgery
Unclear, possibly 1880	Developed surgical treatments for mastoid disease ³ and the anatomical roadmap to the temporal bone from a see-through perspective, starting at the suprameatal triangle (Macewen’s Triangle), a superficial, easily palpable depression in the mastoid surface located between the posterosuperior edge of the external meatus, the supramastoid crest and the vertical tangent along the posterior edge of the meatus ⁵ . Macewen used a dental burr and not chisel and mallet as was customary then.	Neurosurgery, Otolaryngology, Imaginology
1880	Established a training program for nurses ^{1,3,7} , focused on sterilization.	Nursing, Multiprofessional Education
From 1881	Clinical photography for teaching purposes ⁸	Medical Education
Prior to 1884	Cracked-pot percussion sign in hydrocephalus (Macewen’s sign), which may have sprouted from Ferrier’s work ⁴ .	Neurology, Neurosurgery
1893	Publication of <i>Pyogenic Infective Diseases of the Brain and Spinal Cord</i> , and its accompanying volume, <i>Atlas of Head Sections</i> ⁹	Neurology, Neurosurgery, Otorhinolaryngology, Head and Neck Surgery
1916	Working with engineers - and adamant that the hospital would design and produce its own limbs with input from the patients ¹ – he designed the Erskine Hospital Artificial Limb for soldiers that had lost limbs during First World War	Medical Engineering, Multiprofessional Health Teams Rehabilitation
1895	He introduced pneumectomy. Not only a feat in technical surgical skill, but also based on a large experimental work and clinical observation ³ , which, in the process, gave proof of the “molecular cohesion” which holds the pleurae together.	Respiratory Physiology, Pneumology, Thoracic Surgery

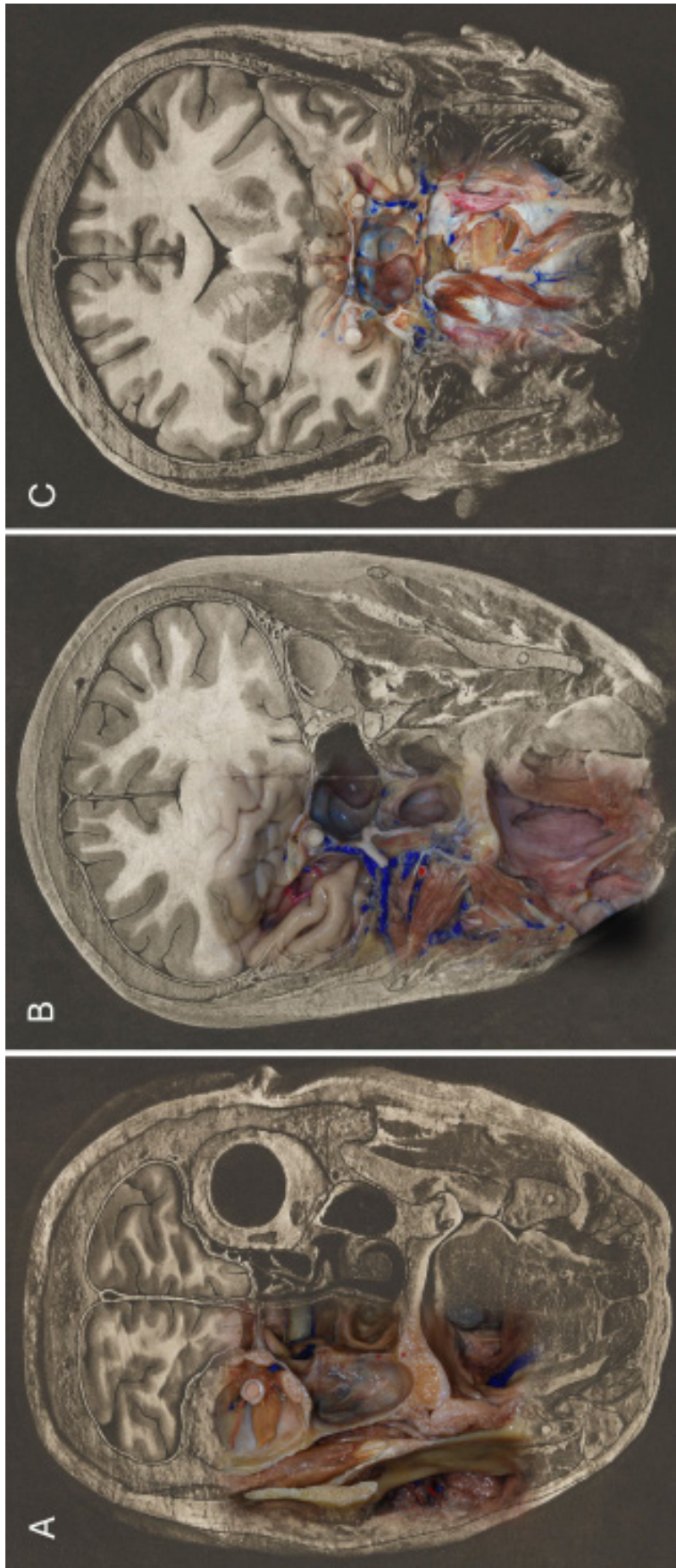


Figure 1. A-C. Stepwise set of coronal cuts from Macewen's Atlas of Coronal Sections (A. Plate A-1. B. Plate B-14. C. Plate A-5), have been embedded with dissections of silicone injected cadaveric heads which progressed - using microneurosurgical techniques - from similarly applied coronal cuts. The dissections were performed at the George Schrader Colter International Microneurosurgical Anatomy Lab - US, under supervision of Professor Albert Rhoton Jr. in an umbrella-protect devised to explore skull base anatomy applied to endoscopic procedures and captured both 2D and 3D images (10-16). Beyond the relationships of the brain with the calvaria, the relationships of the nasal cavity, paranasal sinuses, infratemporal and pterygopalatine fossae, orbits, and pharynx with the cranial compartment were explored. These images exemplify the present and ongoing importance of Macewen's multiplanar anatomical relationships for surgical planning and its successful execution

References

- Records of Erskine Hospital Ltd, veterans' charity, Renfrewshire, Scotland. <https://archiveshub.jisc.ac.uk/search/archives/0314f38a-5816-3cf4-bf08-0295954f0a25>. [Accessed July 1st, 2024].
- Canale DJ. William Macewen and the treatment of brain abscesses: revisited after one hundred years. *JNS*. 1996; 84(1): 133-142. <https://doi.org/10.3171/jns.1996.84.1.0133>
- Macmillan M. Localization and William Macewen's Early Brain Surgery Part I: The Controversy. *Journal of the History of the Neurosciences Basic and Clinical Perspectives*. 2004; 13(4): 297-325. <https://doi.org/10.1080/09647040490881659>
- Macmillan M. Localization and William Macewen's Early Brain Surgery Part II: The Cases. *Journal of the History of the Neurosciences Basic and Clinical Perspectives*. 2005; 14(1): 24-56. <https://doi.org/10.1080/09647040590881793>
- Macmillan M. "I could see, and yet, mon, I could na' see": William Macewen, the agnosias, and brain surgery. *Brain and Cognition*. 2004; 56(1): 63-76. <https://doi.org/10.1016/j.bandc.2004.05.007>
- Rhoton Jr. AL. *Cranial Anatomy and Surgical Approaches*. Schaumburg: Lippincott Williams Wilkins. 2003.
- Pringle JH, Patrick J, Childe CP, Bland-Sutton J, Wheeler WIC, Balance C, Sargent P, Allan GA, Hayward WT. Sir William Macewen CB, MD, FRCS, FRS: Obituary. *The British Medical Journal*. 1924; 603-608.
- Summerly P. Sir William Macewen (1848-1924): Surgeon and Clinical Photographer. *Scottish Medical Journal*. 2007; 52(4): 44-46. <https://doi.org/10.1258/rsmsmj.52.4.44>
- Macewen W. *Atlas of Head Sections; Fifty-Three Engraved Copperplates of Frozen Sections of the Head, and Fifty-Three Key Plates with Descriptive Texts*. Glasgow, MacLehose. 1893.
- Martins C, Campero A, Yasuda A, Alencastro LF, Osawa S, and Rhoton Jr. AL. Anatomy and Osteology of the Skull Base. In: Stamm AC (ed.). *Transnasal Endoscopic Skull Base and Brain Surgery*. 2nd ed. New York: Thieme. 2019. Chapter 1, Part I, 3-14. ISBN 9781626237100
- Martins C, Alencastro LF, Cardoso ACC, Campero A, Yasuda A, Wang J, Alencastro LC, Rhoton Jr. AL. Anatomy of the Nose, Paranasal Sinus and Skull Base. In: Stamm AC (ed), *Transnasal Endoscopic Skull Base and Brain Surgery*. New York: Thieme. 2019. Chapter 2, Part I, 15-35.. ISBN 9781626237100
- Martins C, Yasuda A, Campero A, Alencastro LF, Inoue K, Rhoton Jr. AL. Microsurgical and Endoscopic Anatomy of the Sellar and Parasellar Regions. In: Stamm AC (ed), *Transnasal Endoscopic Skull Base and Brain Surgery*. New York: Thieme. 2019. Chapter 32, Part VI, 211-223. ISBN 9781626237100
- Alencastro LF, Martins C, Rhoton Jr. AL. Transmaxillary Approach to Contralateral Cavernous Sinus. In: Stamm AC (ed.), *Transnasal Endoscopic Skull Base and Brain Surgery*. New York: Thieme. 2019. Chapter 48, Part VIII, 314-326. ISBN 9781626237100
- Cardoso, Brock RS, Martins C, Alencastro LF, Rhoton Jr. AL. Microendoscopic and Endoscopic Anatomy of the Craniovertebral Junction. In: Stamm AC (ed), *Transnasal Endoscopic Skull Base and Brain Surgery*. New York: Thieme. 2019. Chapter 59, Part IX, 361-370. ISBN 9781626237100.
- Martins C, Capel AC, Alencastro LF, Leão C, Rhoton Jr. AL. Endoscopic Assisted Lateral Transatlantal Approach to Craniovertebral Junction. *World Neurosurg*. 2010; 74 (2/3):351-358. <http://doi.org/10.1016/j.wneu.2010.05.037>
- Martins C, Campero A, Alencastro LF, Inoue K, Sekher A, Rhoton Jr. AL. Three-Dimensional Endoscopic Photography of Anatomic Specimens. *World Neurosurgery*. 2018; 120: e730-e736. <https://doi.org/10.1016/j.wneu.2018.08.150>

Antonio Cavalcanti de A Martins

<https://orcid.org/0000-0002-1249-8622>

Carolina Martins

<https://orcid.org/0000-0002-0197-3520>

Marcelo Moraes Valença

<https://orcid.org/0000-0003-0678-3782>

Authors Contribution: ACAM, CM, MMV: Substantial contributions to the conception of the work; reviewing it critically for important intellectual content, final approval of the version to be published, agreement to be accountable for all aspects of the work in ensuring that questions related to the accuracy or integrity of any part of the work are appropriately investigated and resolved.

Conflict of interest: There are no conflict of interest.

Funding: There was no funding.