

History of Medicine

Questioning the anatomical truth: is the dissected arm in 'The Anatomy Lesson of Dr. Nicolaes Tulp' truly exposing the ulnar nerve?

Maria Rosana de Souza Ferreira, André Pukey Oliveira Galvão, Carolina Peixoto Magalhães, Carolina Martins, Marcelo Moraes Valença

Federal University of Pernambuco, Pernambuco, Recife, Brazil

Edited by:
Juliana Ramos de Andrade

Introduction

Autopsies were important events in Holland in the 17th century. One of these autopsies was immortalized in painting, by Rembrandt. “*The Anatomy Lesson of Dr Nicolaes Tulp*” (1632), which shows a dissected forearm. It has been discussed in the literature for decades, with no consensus regarding the white thread that runs in the ulnar aspect of the cadaver’s dissected wrist and little finger. After evaluating the anatomical interpretations suggested by other authors, which include an anatomical variant of the ulnar nerve, we came up with another probable explanation for the presence of this white thread.

Objective

This brief review aims at assessing and interpreting the filamentous structure depicted on the left forearm and hand in Rembrandt's painting. To achieve this, cadaveric dissections were carried out to explore the various anatomical structures depicted in the painting.

Methods

Seeking to replicate the dissected arm depicted in Dr. Tulp's dissection, adult human cadaveric forearms were dissected, highlighting the trajectory of the branch of the ulnar nerve extending towards the little finger.

Conclusion

We suggest that the unexpected long filament depicted on the ulnar aspect of the hand is a detached part from the tendon located in the forearm/hand. Possibly, in order to be painted, it was placed medially rather than adjoining the sectioned part of the tendon in the original location.

Keywords

Art, Anatomy, Peripheral Nerve, Rembrandt, Ulnar Nerve.



Marcelo M. Valença
mmvalenca@yahoo.com.br

Introduction

One of the most famous paintings in the History of Medicine, The Anatomy Lesson of Dr Nicolaes Tulp (1) (Figure 1A-C), was painted in Amsterdam by Rembrandt, in 1632 (2). In this painting, whose arrangement is mostly fictional and intended in telling a story (3), Dr Tulp is teaching muscular anatomy to a group of physicians, taking advantage of a rare opportunity in which a cadaver was allowed to be dissected.

Recent observations have been published regarding real or possible flaws in the anatomy of the dissected arm visible in this painting (3,4). Particularly intriguing is a long white-reddish structure on the ulnar aspect of the cadaver's left hand (Figure 1A and D). Different interpretations have attempted to explain this thread over the forearm and attached to the small finger. Some authors believe that it is an anatomical variant of the ulnar nerve (4,5) (Figure 1E and F).

Rembrandt had no training in anatomy and therefore must have painted by observing an arm already dissected, and the scene fabricated to convey a pleasing message to the commissioners. The first hint of this is the omitted usual order of dissection – usually intended to better take profit from the unpreserved cadaver available, by dissecting initially the most perishable organs. Besides, up to that moment in time, public dissections involved three socially and hierarchically different people: a lector, a demonstrator (or ostensor) and the dissector (or incisor) (6). Dr. Tulp does not fit in any of these roles, except that of the highest financial bidder to the commission (Figure 1A). It seems that the body seen in the picture, known to belong to Adriaan Adriaanszoon (AKA Aris Kindt), a condemned criminal, executed by hanging and allowed to be dissected in public, was painted in separate parts that were eventually brought together (7). Distortions in the construction of the human body, may point to that. Examples of the distortions in this representation (3, 7) include: a) the absence of a neck, b) the lateral deviation of the head, closer to the right shoulder, c) a stumped right arm, having a hand added later, resulting in a disproportionately shorter arm (7) and d) the disproportion between thorax and abdomen – both being expected to be already dissected at this point (3). Even in the dissected arm, anatomical inaccuracies can be seen, one example is the insertion of the hand flexors in the lateral epicondyle, instead of the medial one (8) (Figure 1D).

Dr Tulp was a distinguished anatomist and regarded as the “Dutch Vesalius”. He did his training with Pieter Paauw - a disciple of Hieronymus Fabricius – therefore belonging to the “anatomical lineage” of the University of Padua and connected to Vesalius – what the painting seems to imply in more than one occasion (Figure 1A-C). Andreas Vesalius (1514–1564), while a Professor in Padua, published *De Humani Corporis Fabrica*, in 1543 (9). In this regard, Rembrandt was possibly inspired to paint an arm based on the drawing of Vesalius holding a dissected arm in he frontispiece of this book. (Figure 1C), which may well have been depicted on the viewer's bottom right in “The Anatomy Lesson of Dr Nicolaes Tulp” (Figure 1A and B) (1, 2).

It is uncertain whether Rembrandt painted the arm with the aid of drawings from contemporary books or whether he really drew directly

from the cadaver being dissected. By the early XVII century drawings showing the ventral muscular anatomy of the arm were already available (10), although the cinematic, multipurpose, and multidirectional views of these muscles achieved by Leonardo da Vinci were yet mostly out of circulation (11). But, even nowadays, the anatomy of the arm seems to be poorly understood, given that most medical professionals, trained in anatomy, may not identify anatomical inaccuracies in this painting (5, 7).

This brief report aims at clarifying the nature of filamentous structure depicted on the cadaver's left forearm and hand, in Rembrandt's painting. To achieve this, similar cadaveric dissections were carried out, to more accurately identify the various anatomical structures depicted.

Cadaveric dissections

Seeking to replicate the dissected arm depicted in Dr. Tulp's dissection, the authors dissected adult human cadaveric forearms and hands, as shown in the Figure 1E and F.

Authors' Interpretation

Dr Tulp is believed to be simulating with his left hand the action of the flexor muscular group, which he is, at the same time, pulling with his forceps, being that the reason why this picture is considered a lesson in muscular anatomy. Even though, when magnified (Figure 1E), small neural anatomical details can be recognized. The digital branch of the ulnar nerve being so represented (and in its appropriated trajectory), the authors departed from the interpretation that accounts for the white structure present laterally as a long filament on the ulnar nerve, favored by others (3-7); and, considering the inaccuracies regarding anatomical details that have been listed in the depiction of this cadaver, consider the commonest mistake during dissection, which is to split a single structure and misplace parts of it during depiction.

Misplacement of detached structures is a common mistake for beginners in anatomy, and in dissections carried out hastily (as happens in unpreserved specimens). The filament or thread in question seem to be a detached part from the tendon of the flexor digitalis superficialis muscle, the distal part of which remained attached to the little finger (Figure 1D). Possibly, in order to be painted, it was placed medially, rather than adjoining the sectioned part of the tendon, in its the original location.

In conclusion, the authors believe that the most plausible explanation for the “unknown” structure in The Anatomy Lesson of Dr Nicolaes Tulp (1), by Rembrandt, in 1632, is that it is an artifact of the dissection process, which occurs quite frequently and would have been corrected by an illustrator with a more formal anatomical training.

Not only was this great masterpiece successful in achieving its most immediate effect - namely immortalizing the people that have made its commission, but it also bears historical testimony to important shifts in the medical field, during the Dutch Golden Age; and goes on in time defying the powers of observation and anatomical knowledge of practitioners, as a true lesson in anatomy would certainly do.

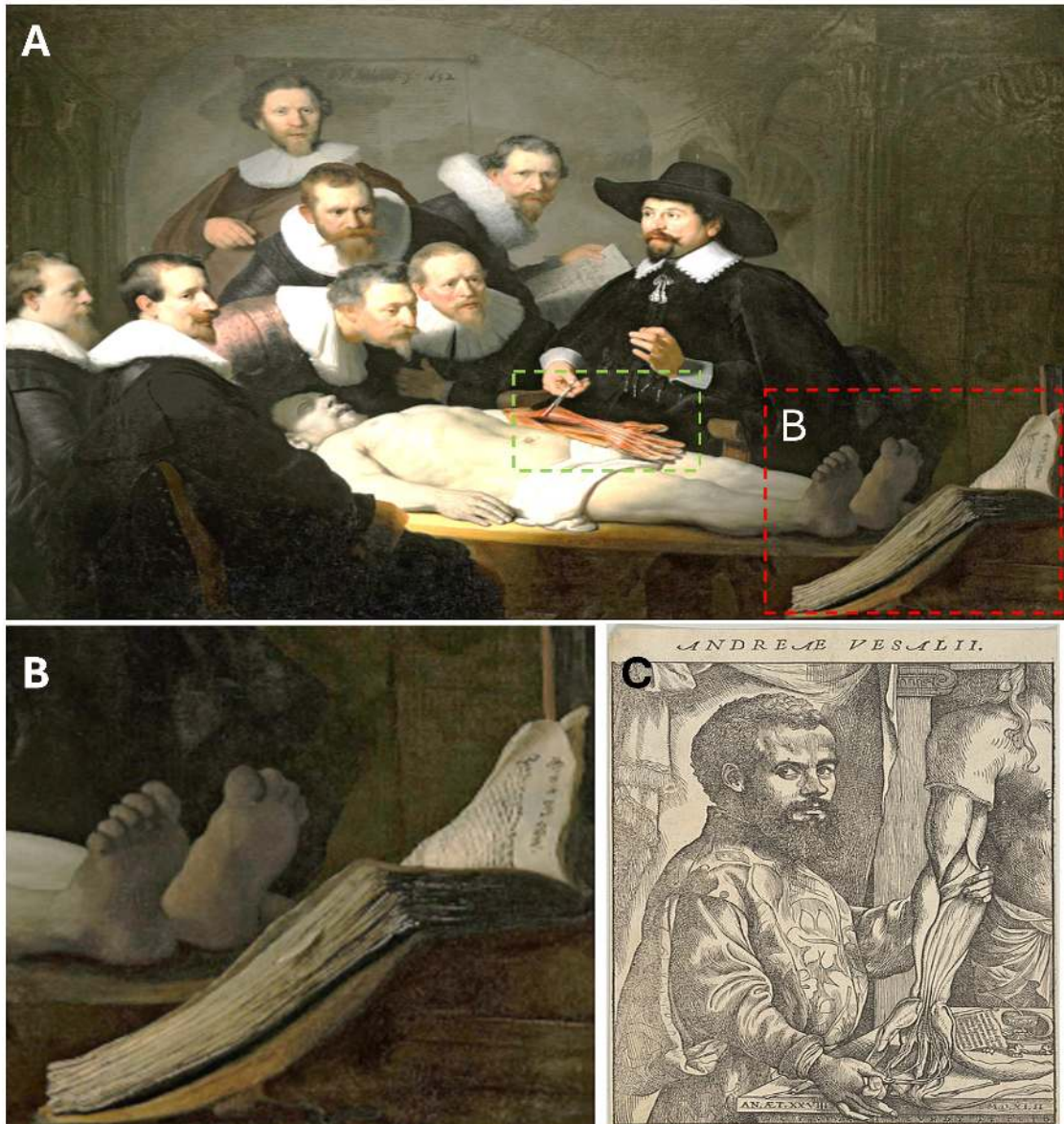
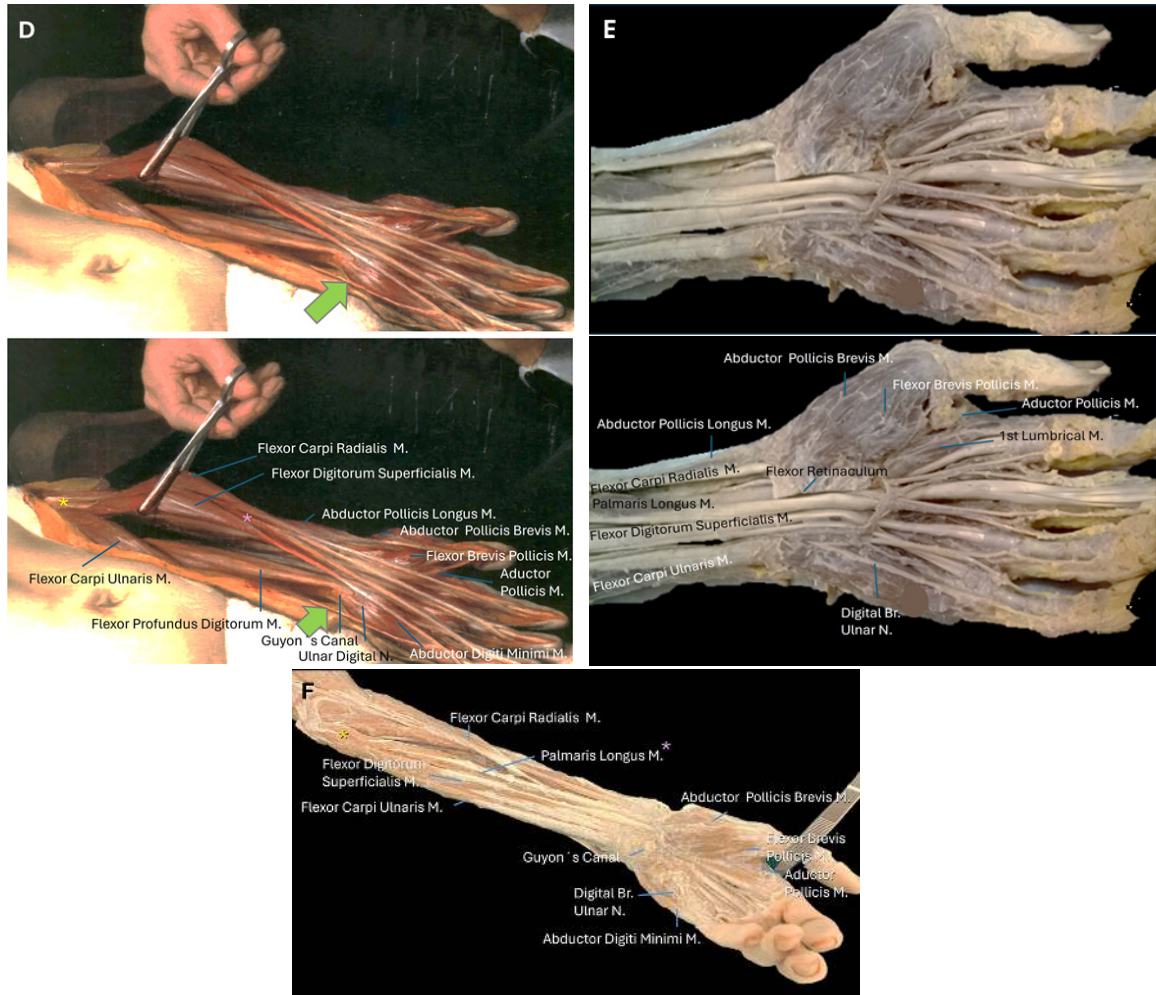


Figure 1. A. "The Anatomy Lesson of Dr Nicolaes Tulp" was painted by Rembrandt, in 1632, following a commission of the Surgeon's Guild, and is held nowadays in the Mauritshuis (1). Two subliminal messages link Dr. Tulp to Vesalius and the "Paduan lineage": First, no lector, demonstrator or dissector are seen in this dissection room. This shift is brought about by Vesalius, that comes to alter this tradition and to personify the three traditional figures. In Rembrandt's representation, this place is given to Dr. Tulp (also known as the "Dutch Vesalius"). Besides, depicted in this commission, are the "advances in the field" - possibly represented by "the latest publication", being held open at the feet of the cadaver and at sight-distance from the participants (red-dotted rectangle). B. Close-up view of the red dotted rectangle in A. The publication, depicted opened at the right bottom corner of Rembrandt's painting, may have been Vesalius 'De Humani Corporis Fabrica' (2, 9). C. Portrait of Andreas Vesalius, depicted in profile, half-length, standing, as he - himself - dissects the cadaver's arm. This depiction serves as the frontispiece for 'De Humani Corporis Fabrica - Libri Septem' it is considered to have motivated the theme for "Dr. Tulp's Lesson".

Continuation Figure 1



D. Close-up view of the green dotted rectangle in A. Detail of the left arm, with a much discussed white thread visible on the forearm (green arrow). Note that this thread is different from a branch that springs from below Guyon's canal, as - possibly - a digital branch of the ulnar nerve. Observing the direction of traction of the flexor digitorum superficialis, the thread may be a displaced piece of this tendon. M.: Muscle. Yellow asterisk: The superficial group of flexors muscles have been attached to the lateral epicondyle, instead of the medial one, an anatomical inaccuracy frequently mentioned. Pink asterisk: The palmaris longus muscle may be compressed between the flexor carpi and digitorum superficialis muscles, as they are being tractioned upwards. However, it is not uncommon that this muscle, which has a well-defined tendon, is absent. E. Enlarged view of the wrist, in cadaveric specimen. Note the course of the digital branch of the ulnar nerve. F. Left forearm dissection, performed to compare with the cadaveric dissection presented in C. The palmaris longus muscle is well defined here (pink asterisk). The flexor muscular group is attached to the medial epicondyle (yellow asterisk). A long branch of the ulnar nerve that runs along the little finger is presented, as in Rembrandt's representation, it courses in close relation to the pisiform and Guyon's canal.

References

1. Rembrandt. The Anatomy Lesson of Dr. Tulp. Oil on canvas, 216.5 cm × 169.5 cm, 1632. Mauritshuis, The Hague.
2. Masquelet AC. The anatomy lesson of Dr. Tulp. *J Hand Surg Am.* 2005;30(4):379–81. Doi 10.1016/J.JHSB.2004.11.005
3. Afek A, Friedman T, Kugel C, Barshack I, Lurie DJ. Dr. Tulp's anatomy lesson by Rembrandt: The third day hypothesis. *Isr Med Assoc J.* 2009;11(7):389–92.
4. Jackowe DJ, Moore MK, Bruner AE, Fredieu JR. New Insight Into the Enigmatic White Cord in Rembrandt's The Anatomy Lesson of Dr. Nicolaes Tulp (1632). *J Hand Surg Am.* 2007;32(9):1471–6. Doi 10.1016/j.jhsa.2007.07.006
5. Ijpm FFA, Graaf RC Van De, Nicolai JA, Meek MF. The Anatomy Lesson of the Painting With a Dissected Left Forearm of a Dutch Male Cadaver. 2006;(1632):882–91. Doi 10.1016/j.jhsa.2006.02.014
6. Klestinec C. Theaters of Anatomy. Students, Teachers, and Traditions of Dissection in Renaissance Venice. The Johns Hopkins University Press, Baltimore, 2011.
7. Di Matteo B, Tarabella V, Filardo G, Tomba P, Viganò A, Marcacci M. Nicolaes Tulp: The Overshadowed Subject in The Anatomy Lesson of Dr. Nicolaes Tulp. *Clin Orthop Relat Res.* 2016;474(3):625–9. Doi 10.1007/s11999-015-4686-y
8. J G. Rembrandt's anatomy of Dr. Nicolaas Tulp. *Arch Chir Neerl.* 1977;29(2):83–91.
9. Andreas Vesalius (1514-1564). *De Humani Corporis Fabrica. Epitome. Tabula Sex.* Saunders JBDec, O'Malley C. The Illustrations of the Works of Andreas Vesalius of Brussels. 1950. The World Publishing Group
10. Rifkin, BA, Ackerman MJ, Folkenberg J. *Human Anatomy. Depicting the Body from Renaissance to Today.* Thames & Hudson, London, 2006.
11. Clayton M and Philo R. Leonardo da Vinci . Anatomist. Royal Collection Publications, London, 2012.

Maria Rosana de Souza Ferreira
<https://orcid.org/0000-0003-1166-5342>
André Pukey Oliveira Galvão
<https://orcid.org/0000-0002-3914-2255>
Carolina Peixoto Magalhães
<https://orcid.org/0000-0003-3556-1011>
Carolina Martins
<https://orcid.org/0000-0002-0197-3520>
Marcelo Moraes Valença
<https://orcid.org/0000-0003-0678-3782>

Contributions for Authors: MRSF, APOG: Data gathering. CPM, CM, MMV: Critical review of document

Conflict of interest: There are no conflict of interest.

Funding: There was no funding.